

Personal Quick Reference Sheets

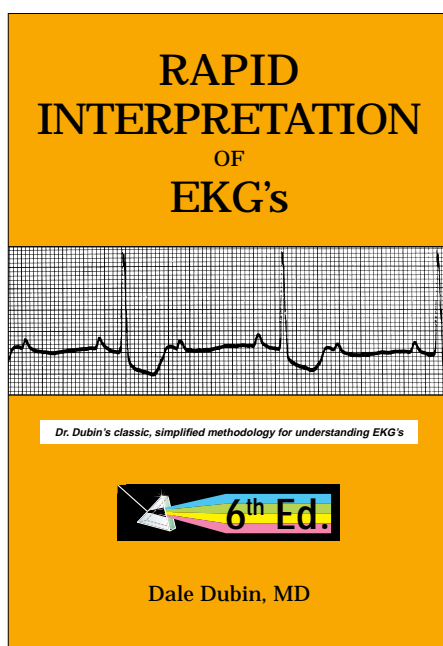
(pages 333 to 346)

from: ***Rapid Interpretation of EKG's***

by Dale Dubin, MD

COVER Publishing Co., P.O. Box 1092, Tampa, FL 33601, USA

The owner of this book may remove pages 333 through 346 to carry as a personal quick reference, however, copying for or by others is strictly prohibited. The entire text of *Rapid Interpretation of EKG's* is fully protected by domestic United States copyright as well as the Universal Copyright Convention, and all rights of absolute imprimatur are enforced by COVER Publishing Co.



May humanity benefit from your knowledge,

Dale Dubin

Web Sites:

Physicians and medical students: www.theMDSite.com

Nurses and nurses in training: www.CardiacMonitors.com

Emergency medical personnel: www.EmergencyEKG.com

Personal Quick Reference Sheets

Dubin's Method for Reading EKG's

from: *Rapid Interpretation of EKG's*

by Dale Dubin, MD

COVER Publishing Co., P.O. Box 1092, Tampa, FL 33601, USA

1. RATE (pages 65-96)

Say "300, 150, 100" ... "75, 60, 50"

- but for bradycardia:
rate = cycles/6 sec. strip X 10

2. RHYTHM (pages 97-202)

Identify the basic rhythm, then scan tracing for prematurity, pauses, irregularity, and abnormal waves.

- Check for: P before each QRS.
QRS after each P.
- Check: PR intervals (for AV Blocks).
QRS interval (for BBB).
- If Axis Deviation, rule out Hemiblock.

3. AXIS (pages 203-242)

- QRS above or below baseline for Axis Quadrant (for Normal vs. R. or L. Axis Deviation).
For Axis in degrees, find isoelectric QRS in a limb lead of Axis Quadrant using the "Axis in Degrees" chart.
- Axis rotation in the horizontal plane: (chest leads)
find "transitional" (isoelectric) QRS.

4. HYPERTROPHY (pages 243-258)

Check V_1 { P wave for atrial hypertrophy.
R wave for Right Ventricular Hypertrophy.
S wave depth in V_1 ...
+ R wave height in V_5 for Left Ventricular Hypertrophy.

5. INFARCTION (pages 259-308)

Scan all leads for:

- Q waves
- Inverted T waves
- ST segment elevation or depression

Find the location of the pathology (in the Left ventricle),
and then identify the occluded coronary artery.

Personal Quick Reference Sheets

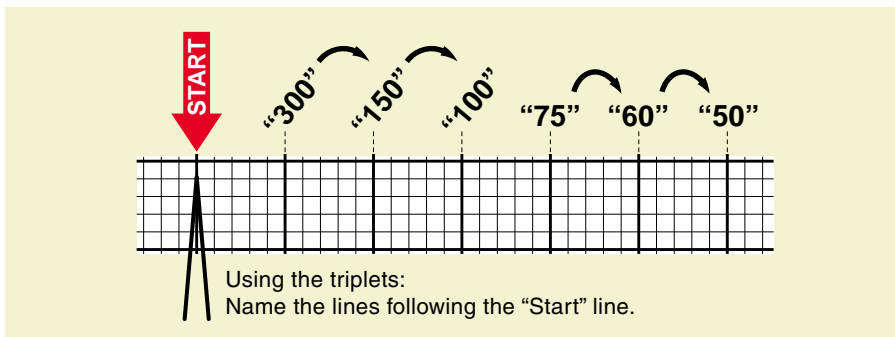
Rate (pages 65 to 96)

from: *Rapid Interpretation of EKG's*

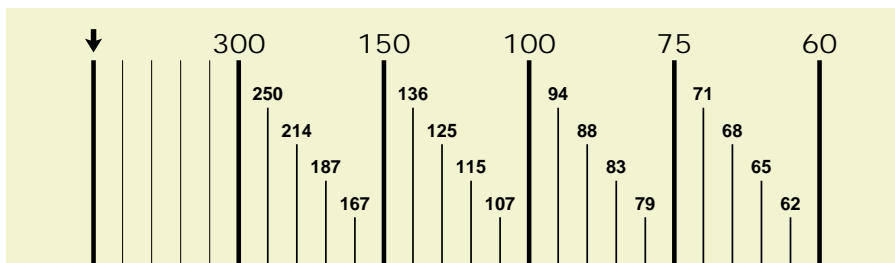
by Dale Dubin, MD

COVER Publishing Co., P.O. Box 1092, Tampa, FL 33601, USA

Determine Rate by Observation (pages 78-88)



Fine division/rate association: reference (page 89)



May be calculated: $\frac{1500}{\text{mm. between similar waves}} = \text{RATE}$

Bradycardia (slow rates) (pages 90-96)

- Cycles/6 second strip $\times 10 = \text{Rate}$
- When there are 10 large squares between similar waves, the rate is 30/minute.

Sinus Rhythm: origin is the SA Node ("Sinus Node"), normal sinus rate is 60 to 100/minute.

- Rate more than 100/min. = *Sinus Tachycardia* (page 68).
- Rate less than 60/min. = *Sinus Bradycardia* (page 67).

Determine any co-existing, independent (atrial/ventricular) rates:

- Dissociated Rhythms: (pages 155, 157, 186-189)
A Sinus Rhythm (or atrial rhythms) may co-exist with an independent rhythm from an automaticity focus of a lower level. Determine rate of each.

Irregular Rhythms: (pages 107-111)

- With Irregular Rhythms (such as Atrial Fibrillation) always note the general (average) ventricular rate (QRS's per 6-sec. strip $\times 10$) or take the patient's pulse.

Personal Quick Reference Sheets

Rhythm (pages 97 to 111)

from: **Rapid Interpretation of EKG's**
 by Dale Dubin, MD
 COVER Publishing Co., P.O. Box 1092, Tampa, FL 33601, USA

★ **Identify basic rhythm...**

...then scan entire tracing for pauses, premature beats, irregularity, and abnormal waves.

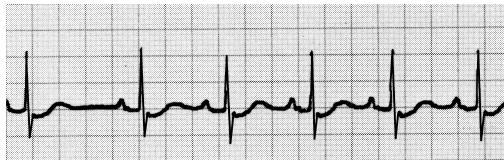
★ **Always:**

- Check for: P before each QRS.
QRS after each P.
- Check: PR intervals (for AV Blocks).
QRS interval (for BBB).
- Has QRS vector shifted outside normal range? (to rule out Hemiblock).

Irregular Rhythms (pages 107-111)

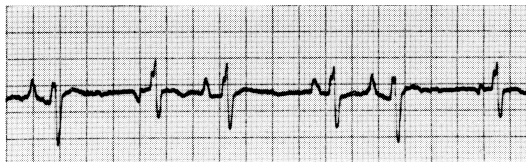
Sinus Arrhythmia (page 100)

Irregular rhythm that varies with respiration.
 All P waves are identical.
 Considered normal.



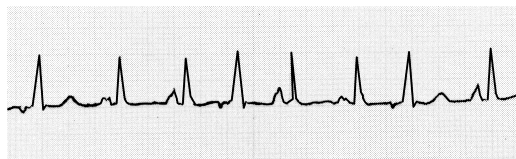
Wandering Pacemaker (page 108)

Irregular rhythm. P waves change shape as pacemaker location varies.
 Rate under 100/minute...



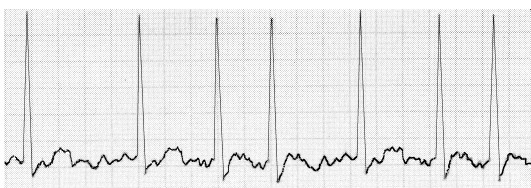
...but if the rate exceeds 100/minute, then it is called

Multifocal Atrial Tachycardia (page 109)



Atrial Fibrillation (pages 110, 164-166)

Irregular ventricular rhythm. Erratic atrial spikes (no P waves) from multiple atrial automaticity foci. Atrial discharges may be difficult to see.



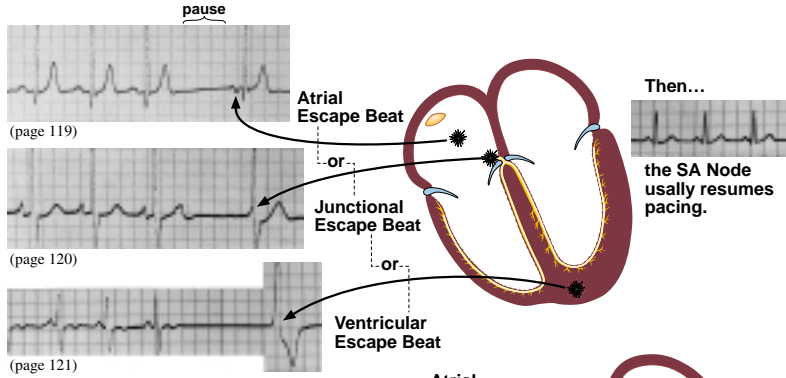
Personal Quick Reference Sheets

Rhythm continued (pages 112 to 145)

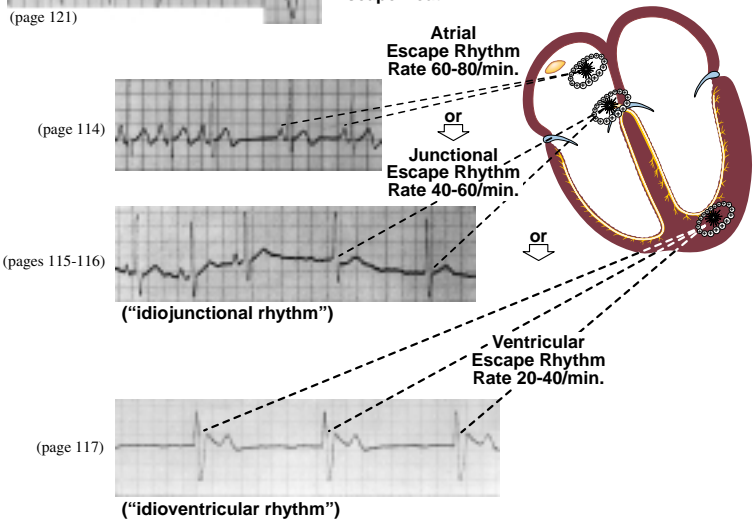
from: *Rapid Interpretation of EKG's*
 by Dale Dubin, MD
 COVER Publishing Co., P.O. Box 1092, Tampa, FL 33601, USA

Escape (pages 112-121) – the heart's response to a pause in pacing

- An unhealthy Sinus (SA) Node may fail to emit a pacing stimulus ("Sinus Block"); this pause may evoke an escape beat from an automaticity focus.

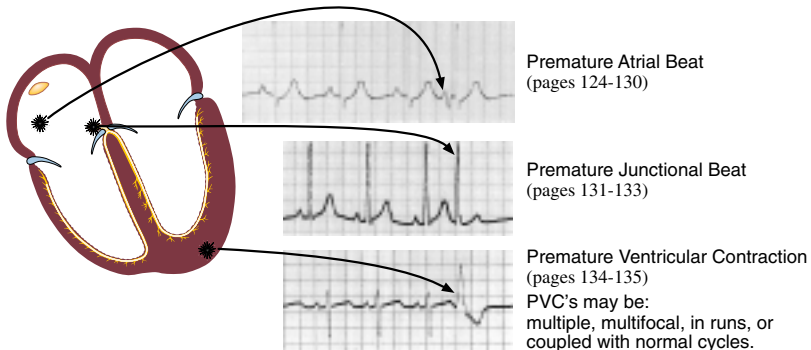


- But a sick Sinus (SA) Node may cease pacing ("Sinus Arrest"), causing an automaticity focus to "escape" to assume pacemaker status.



Premature Beats (pages 122-145) – from an irritable automaticity focus

- An irritable automaticity focus may suddenly discharge, producing a:



Rhythm continued (pages 146 to 172)

from: *Rapid Interpretation of EKG's*

by Dale Dubin, MD

COVER Publishing Co., P.O. Box 1092, Tampa, FL 33601, USA

Tachyarrhythmias (pages 146-172), "focus" = automaticity focus

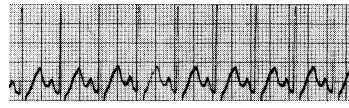	150	250	350	450
Rates:	Paroxysmal Tachycardia	Flutter	Fibrillation multiple foci discharging	

Paroxysmal (sudden) Tachycardia ...rate: 150-250/min. (pages 146-163)

"Supraventricular Tachycardia" (page 153)

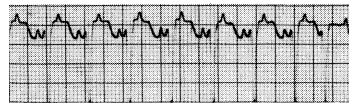Paroxysmal Atrial Tachycardia

An irritable atrial focus discharging at 150-250/min. produces a normal wave sequence, if P' waves are visible. (page 149)



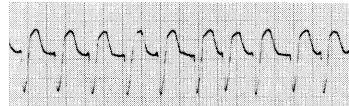
• P.A.T. with block

Same as P.A.T. but only every second (or more) P' wave produces a QRS. (page 150)



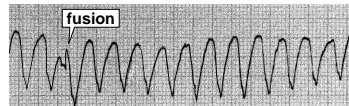
Paroxysmal Junctional Tachycardia

AV Junctional focus produces a rapid sequence of QRS-T cycles at 150-250/min. QRS may be slightly widened. (pages 151-153)



Paroxysmal Ventricular Tachycardia

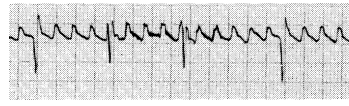
Ventricular focus produces a rapid (150-250/min.) sequence of (PVC-like) wide ventricular complexes. (pages 154-158)



Flutter ...rate: 250-350/min.

Atrial Flutter

A continuous ("saw tooth") rapid sequence of atrial complexes from a single rapid-firing atrial focus. Many flutter waves needed to produce a ventricular response. (pages 159, 160)



Ventricular Flutter (pages 161, 162) also see "Torsades de Pointes" (pages 158, 345)

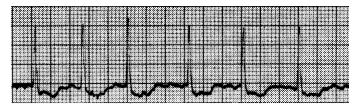
A rapid series of smooth sine waves from a single rapid-firing ventricular focus; usually in a short burst leading to Ventricular Fibrillation.



Fibrillation ...erratic (multifocal) rapid discharges at 350 to 450/min. (pages 167-170)

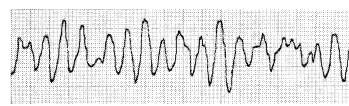
Atrial Fibrillation (pages 110, 164-166)

Multiple atrial foci rapidly discharging produce a jagged baseline of tiny spikes. Ventricular (QRS) response is irregular.



Ventricular Fibrillation (pages 167-170)

Multiple ventricular foci rapidly discharging produce a totally erratic ventricular rhythm without identifiable waves. Needs **immediate** treatment.



Personal Quick Reference Sheets

Rhythm: (“heart”) blocks (pages 173 to 202)

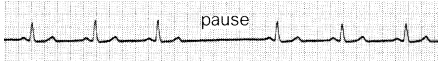
from: *Rapid Interpretation of EKG’s*

by Dale Dubin, MD

COVER Publishing Co., P.O. Box 1092, Tampa, FL 33601, USA

Sinus (SA) Block (page 174)

An unhealthy Sinus (SA) Node misses one or more cycles (sinus pause)...



the Sinus Node usually resumes pacing, but the pause may evoke an “escape” response from an automaticity focus. (pages 119-121)

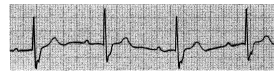AV Block (pages 176-189)

Blocks that delay or prevent atrial impulses from reaching the ventricles.

★ Always Check: • is every P wave followed by a QRS? • PR intervals less than one large square?

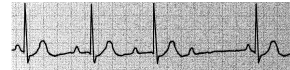
1° AV Block ...prolonged PR interval (pages 176-178).

PR interval is prolonged to greater than .2 sec (one large square).

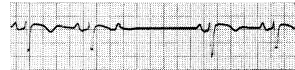


2° AV Block ... some P waves without QRS response (page 179-185)

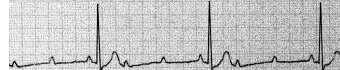
Wenckebach ...PR gradually lengthens with each cycle until the last P wave in the series does not produce a QRS. (pages 180-182, 183)



Mobitz ...some P waves don't produce a QRS response. If “intermittent,” an occasional QRS is dropped. (pages 181-183)

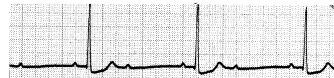

More advanced Mobitz block may produce a 3:1 (AV) pattern or even higher AV ratio (page 181).



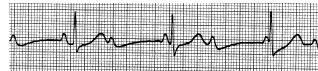
2:1 AV Block ...may be Mobitz or Wenckebach. (pages 182, 183)

PR length and QRS width or vagal maneuvers help differentiate.

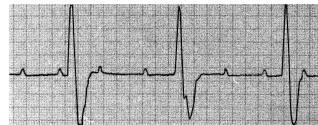


3° (“complete”) AV Block ...no P wave produces a QRS response (pages 186-190)

3° Block: P waves—SA Node origin. QRS’s—if narrow, and if the ventricular rate is 40 to 60 per min., then origin is a Junctional focus. (page 188)



3° Block: P waves—SA Node origin. QRS’s—if PVC-like, and if the ventricular rate is 20 to 40 per min., then origin is a Ventricular focus. (page 189)



Bundle Branch Block ...find R,R' in right or left chest leads (pages 191-202)

Right BBB (pages 194-196)

Left BBB (pages 194-197)

★ Always Check:
• is QRS within 3 tiny squares?



QRS in V₁ or V₂

With Bundle Branch Block the criteria for ventricular hypertrophy are unreliable.



QRS in V₅ or V₆

Caution: With Left BBB infarction is difficult to determine on EKG.

Hemiblock ...block of Anterior or Posterior fascicle of the Left Bundle Branch. (pages 295-305)

★ Always Check:
• has Axis shifted outside Normal range?

Anterior Hemiblock

Axis shifts Leftward → L.A.D.
look for Q₁S₃
(pages 297-299)

Posterior Hemiblock

Axis shifts Rightward → R.A.D.
look for S₁Q₃
(pages 300-302)

Personal Quick Reference Sheets

Axis (pages 203 to 242)

from: *Rapid Interpretation of EKG's*

by Dale Dubin, MD

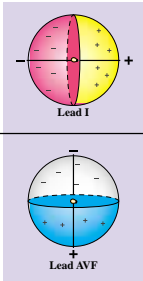
COVER Publishing Co., P.O. Box 1092, Tampa, FL 33601, USA

General Determination of Electrical Axis (pages 203-231)

Is QRS positive (⌚) or negative (⌚) in leads I and AVF?

Is Axis Normal? (page 227)

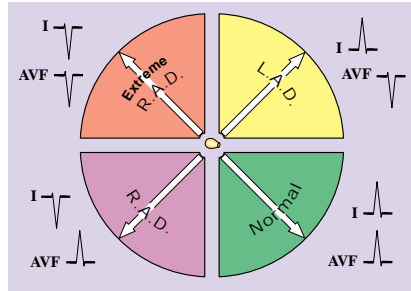
First Determine Axis Quadrant (pages 214-231)



QRS in lead I (pages 215-222)
 ...if the QRS is Positive (mainly above baseline), then the Vector points to positive (patient's left) side.

Normal: { QRS upright in I and AVF
 "two thumbs-up" sign

QRS in lead AVF (pages 223-226)
 ...if the QRS is mainly Positive, then the Vector must point downward to positive half of the sphere.

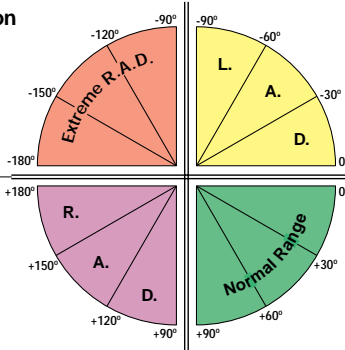


Axis in Degrees (pages 233, 234) (Frontal Plane)

After locating Axis Quadrant, find limb lead where QRS is most isoelectric:

Extreme Right Axis Deviation

lead	Axis
I	-90°
AVL	-120°
III	-150°
AVF	-180°



Left Axis Deviation

lead	Axis
I	-90°
AVR	-60°
II	-30°
AVF	0°

Right Axis Deviation

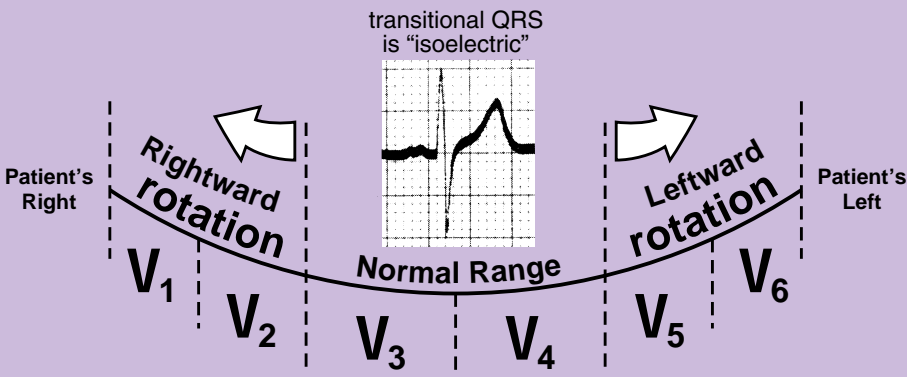
lead	Axis
AVF	+180°
II	+150°
AVR	+120°
I	+90°

Normal Range

lead	Axis
AVF	0°
III	+30°
AVL	+60°
I	+90°

Axis Rotation (left/right) in the Horizontal Plane (pages 236-242)

Find transitional (isoelectric) QRS in a chest lead.



Personal Quick Reference Sheets

Hypertrophy (pages 243 to 258)

from: *Rapid Interpretation of EKG's*

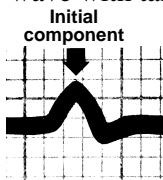
by Dale Dubin, MD

COVER Publishing Co., P.O. Box 1092, Tampa, FL 33601, USA

Atrial Hypertrophy (pages 245-249)

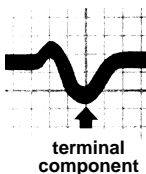
Right Atrial Hypertrophy (page 248)

- large, diphasic P wave with tall initial component.



Left Atrial Hypertrophy (page 249)

- large, diphasic P wave with wide terminal component.



Ventricular Hypertrophy (pages 250-258)

Right Ventricular Hypertrophy (pages 250-252)

- R wave greater than S in V_1 , but R wave gets progressively smaller from $V_1 - V_6$.
- S wave persists in V_5 and V_6 .
- R.A.D. with slightly widened QRS.
- Rightward rotation in the horizontal plane.

Left Ventricular Hypertrophy (pages 253-257)

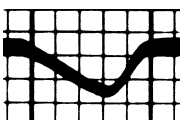
S wave in V_1 (in mm.)

+ R wave in V_5 (in mm.)

Sum in mm. is more than 35 mm. with L.V.H.

- L.A.D. with slightly widened QRS.
- Leftward rotation in the horizontal plane.

Inverted T wave:
slants downward
gradually,



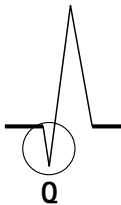
but up rapidly.

Personal Quick Reference Sheets

Infarction (pages 259 to 308)

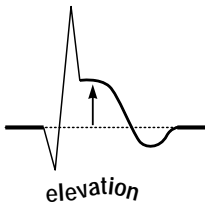
from: **Rapid Interpretation of EKG's**
 by Dale Dubin, MD
 COVER Publishing Co., P.O. Box 1092, Tampa, FL 33601, USA

Q wave = Necrosis (significant Q's only) (pages 272-284)



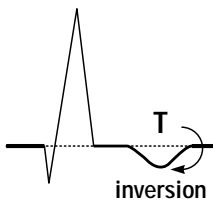
- Significant Q wave is one millimeter (one small square) wide, which is .04 sec. in duration...
 ... or is a Q wave 1/3 the amplitude (or more) of the QRS complex.
- Note those leads (omit AVR) where significant Q's are present ... see next page to determine infarct location, and to identify the coronary vessel involved.
- Old infarcts: significant Q waves (like infarct damage) remain for a lifetime. To determine if an infarct is acute, see below.

ST (segment) elevation = (acute) Injury (pages 266-271) (also Depression)



- Signifies an acute process, ST segment returns to baseline with time.
- ST elevation associated with significant Q waves indicates an acute (or recent) infarct.
- A tiny "non-Q wave infarction" appears as significant ST segment elevation without associated Q's. Locate by identifying leads in which ST elevation occurs (next page).
- ST depression (persistent) may represent "subendocardial infarction," which involves a small, shallow area just beneath the endocardium lining the left ventricle. This is also a variety of "non-Q wave infarction." Locate in the same manner as for infarction location (next page).

T wave inversion = Ischemia (pages 264, 265)



- Inverted T wave (of ischemia) is symmetrical (left half and right half are mirror images). Normally T wave is upright when QRS is upright, and vice versa.
- Usually in the same leads that demonstrate signs of acute infarction (Q waves and ST elevation).
- Isolated (non-infarction) ischemia may also be located; note those leads where T wave inversion occurs, then identify which coronary vessel is narrowed (next page).

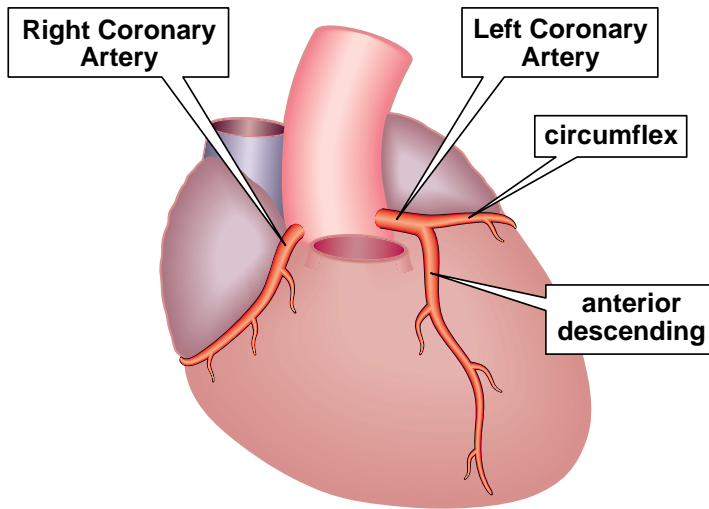
NOTE: Always obtain patient's previous EKG's for comparison!

Infarction Location — and — Coronary Vessel Involvement

(pages 259 to 308)

from: *Rapid Interpretation of EKG's*
by Dale Dubin, MD
COVER Publishing Co., P.O. Box 1092, Tampa, FL 33601, USA

Coronary Artery Anatomy (page 291)



Infarction Location/Coronary Vessel Involvement (pages 278-294)

Posterior

- large R with ST depression in V₁ & V₂
- *mirror test* or *reversed transillumination test* (Right Coronary Artery) (pages 282-286)

Lateral

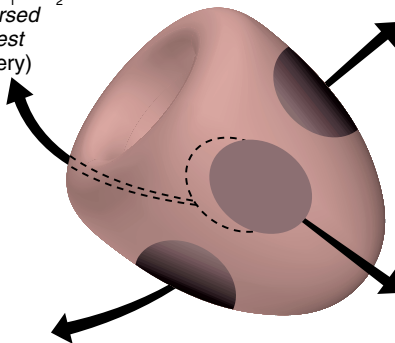
Q's in lateral leads I and AVL (Circumflex Coronary Artery) (pages 280, 292)

Inferior

(diaphragmatic)
Q's in inferior leads II, III, and AVF (R. or L. Coronary Artery) (pages 281, 294)

Anterior

Q's in V₁, V₂, V₃, and V₄ (Anterior Descending Coronary Artery) (pages 278, 292)



Miscellaneous (pages 309 to 328)

from: *Rapid Interpretation of EKG's*

by Dale Dubin, MD

COVER Publishing Co., P.O. Box 1092, Tampa, FL 33601, USA

Pulmonary Embolism (pages 312, 313)


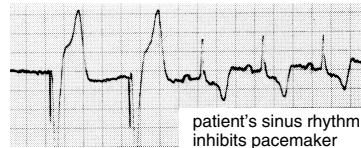
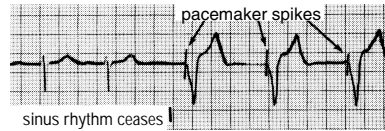
- $S_1 Q_3 L_3$ – wide S in I, large Q and inverted T in III.
- acute Right BBB (transient, often incomplete)
- R.A.D. and clockwise rotation
- inverted T waves $V_1 \rightarrow V_4$ and ST depression in II.

Artificial Pacemakers (pages 321-326)

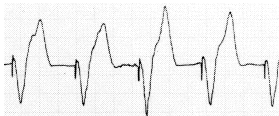Modern artificial pacemakers have sensing capabilities and also provide a regular pacing stimulus. This electrical stimulus records on EKG as a tiny vertical spike that appears just before the “captured” cardiac response.

Demand Pacemakers: (page 301)

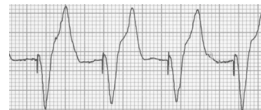- are “triggered” (activated) when the patient’s own rhythm ceases or slows markedly.
- are “inhibited” (cease pacing) if the patient’s own rhythm resumes at a reasonable rate.
- will “reset” pacing (at same rate) to synchronize with a premature beat.



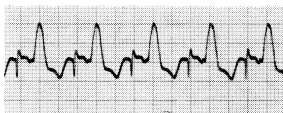
Pacemaker Impulse (delivery modes)



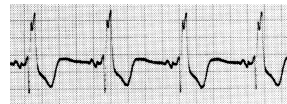
Ventricular Pacemaker (page 323)
(electrode in Right Ventricle)



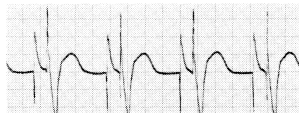
(Asynchronous) Epicardial Pacemaker
Ventricular impulse not linked to atrial activity.



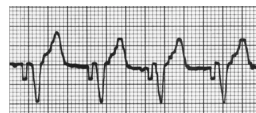Atrial pacemaker (page 323)



Atrial Synchronous Pacemaker (page 323)
P wave sensed, then after a brief delay, ventricular impulse is delivered.



Dual Chamber (AV sequential) Pacemaker
(page 323)



External Non-invasive Pacemaker
(page 326)

Personal Quick Reference Sheets

Miscellaneous continued

from: *Rapid Interpretation of EKG's*

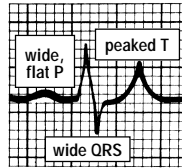
by Dale Dubin, MD

COVER Publishing Co., P.O. Box 1092, Tampa, FL 33601, USA

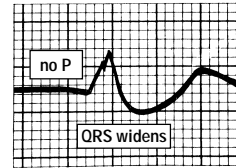
Electrolytes

Potassium (pages 314, 315)

Increased K⁺ (page 314)
(hyperkalemia)

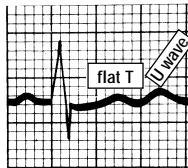


moderate

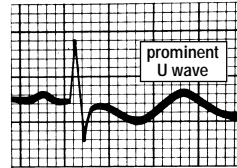


extreme

Decreased K⁺ (pages 315)
(hypokalemia)



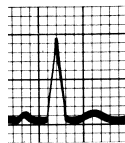
moderate



extreme

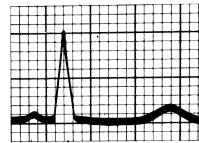
Calcium (page 316)

Hyper Ca⁺⁺



short QT

Hypo Ca⁺⁺




prolonged QT

Digitalis (pages 317-319)

EKG appearance with digitalis (“digitalis effect”)

- remember Salvador Dali.
- T waves depressed or inverted.
- QT interval shortened.



Digitalis Excess (blocks)

- SA Block
- P.A.T. with Block
- AV Blocks
- AV Dissociation

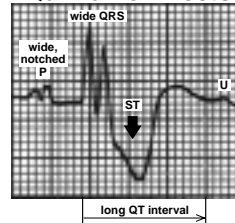
Digitalis Toxicity

- (irritable foci firing rapidly)
- Atrial Fibrillation
- Junctional or Ventricular Tachycardia
- multiple P.V.C.'s
- Ventricular Fibrillation

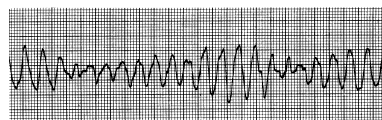
Quinidine (page 320)

• EKG appearance with quinidine (page 320)

Quinidine Effects



• Excess quinidine or other medications that block potassium channels (or even low serum potassium) may initiate... (page 158)



Torsades de Pointes

